Accepted: 3 December 2017

DOI: 10.1111/clr.13119

ORIGINAL RESEARCH

WILEY CLINICAL ORAL IMPLANTS RESEARCH

Immediate and flapless implant insertion and provisionalization using autogenous bone grafts in the esthetic zone: 5-year results

Robert Noelken[1,2] | Maximilian Moergel[2] | Martin Kunkel[3] | Wilfried Wagner[2]

[1]Private Practice for Oral Surgery, Lindau/Lake Constance, Germany

[2]Department of Oral and Maxillofacial Surgery – Plastic Surgery, University Medical Center, Johannes Gutenberg University of Mainz, Mainz, Germany

[3]Department of Oral and Maxillofacial Surgery, University Hospital of Bochum, Bochum, Germany

Correspondence
Robert Noelken, Private Practice for Oral Surgery, Lindau/Lake Constance, Germany.
Email: rnoelken@me.com

Funding information
Astra Tech AB, Moelndal, Sweden, Grant to the University Medicine of Mainz, Germany

Abstract

Objectives: As the 2-year results for immediately inserted and provisionalized implants have been reported, it remained an open issue, whether the initially high success rates and the esthetic outcome remain stable for longer observation periods. Therefore, this prospective study examines the 5-year hard and soft tissue changes at implants placed in the anterior maxilla.

Material and methods: Meanwhile, 37 microthreaded implants were placed in 21 patients into extraction sockets with and without facial bone deficiencies by a flapless approach. Facial gaps and bony defects were grafted with autogenous bone chips. The implants were immediately provisionalized. The primary outcome parameters were the interproximal marginal bone level and the thickness of the facial bony wall. Implant success and Pink Esthetic Score (PES) were considered as secondary outcome parameters.

Results: Two patients with four implants withdrew from the study (dropouts), and the remaining 33 implants were still in function at a follow-up period of 68 months. Marginal bone height averaged 0.04 mm coronal to the implant shoulder. The thickness of the facial bony lamellae increased significantly between pre-op examination and 1-year follow-up (p = .002) and thereafter remained stable. Within 5 years of follow-up, 24 of 33 implants were clinically stable, free of signs and symptoms, and showed bone loss less than 1 mm. The mean PES ratings improved slightly from 10.7 pre-operatively to 11.7 at the last follow-up (p = .02).

Conclusions: Interproximal marginal bone levels, survival rates, and esthetic results remain stable at the 5-year follow-up in implants used in an immediate insertion, reconstruction, and provisionalization concept. Facial marginal bone levels decreased slightly; however, this reduction did not affect the PES so far.

KEYWORDS

autogenous bone graft, facial bony defect, flapless, immediate implant placement, immediate provisionalization

1 | INTRODUCTION

Immediate implant placement and immediate restoration aim at the preservation of the peri-implant bone and soft tissues to achieve long-term osseointegration in combination with the reestablishment of a natural, and thus, esthetic peri-implant mucosa (De Kok, Chang, Moriarty & Cooper, 2006; Kan, Rungcharassaeng & Lozada, 2003; Noelken, Morbach, Kunkel & Wagner, 2007). Although the concept of

immediate functional implant restoration has been established almost 20 years ago (Wöhrle, 1998), it is still subject of a controversial discussion (Chen & Buser, 2009, 2014). Clinical studies that document high survival and success rates are available for short-term follow-up (De Bruyn et al., 2013); however, long-term results are still rare (Cooper et al., 2014; Cosyn et al., 2016; Mertens & Steveling, 2011).

The contemporary patient's demands are not only a "functionally stable implant", but moreover an esthetic and functional rehabilitation in short treatment time (Arora, Khzam, Roberts, Bruce & Ivanovski, 2017; Fugl et al., 2017). Thus, on principle, the treatment concept of immediate insertion and provisionalization seems to fit perfectly to the anterior esthetic zone, but soft tissue changes and the esthetic results around those implant restoration are not always favorable. It is well known that immediate implant insertion using a flap technique without grafting the facial defect between implant surface and facial bony lamella may lead to a significant bone resorption at the alveolar contour (Botticelli, Berglundh & Lindhe, 2004; Ferrus et al., 2010; Paolantonio et al., 2001; Sanz et al., 2010). Specifically, insufficient facial defect grafting (Chen & Buser, 2014; Khzam et al., 2015) in combination with facial angulation and orientation "outside" of the bony envelope of the implant body proved to have a higher risks for mid-facial recessions (Chen, Darby & Reynolds, 2007; Evans & Chen, 2008; Le, Borzabadi-Farahani & Pluemsakunthai, 2014).

As a consequence, several authors recommended the use of the immediate insertion and provisionalization method only in patients with a thick mucosal biotype (Cosyn, De Bruyn & Cleymaet, 2013a; Cosyn et al., 2013b) and with an intact facial bone lamella without any deficiency (Cornelini, Cangini, Covani & Wilson, 2005; Cosyn et al., 2011; Kan et al., 2003).

For some years, we tried to overcome this limitations by strictly aligning immediately inserted implants to the palatal aspect of the extraction site and, thus, rigorously respect the bony envelope and even create additional space for facial defect grafting with autogenous bone particles (Noelken, Neffe, Kunkel & Wagner, 2014; Noelken, Oberhansl, Kunkel & Wagner, 2016).

The aim of this prospective study was to analyze the maintenance of marginal bone support, the survival rate, and the soft tissue esthetics after a follow-up of at least 5 years around immediately placed and restored OsseoSpeed™ implants in the esthetic zone of the maxilla using a flapless approach.

2 | MATERIALS AND METHODS

The primary outcome parameter of this study was the peri-implant marginal bone stability as reflected by interproximal marginal bone height and the dimension of the facial bony wall. The secondary outcome parameters were implant success, as well as peri-implant soft tissue esthetics.

Study design, inclusion/exclusion criteria, demographic data, and treatment modalities have been described in detail earlier in the context of the 2-year results (Noelken et al., 2014). Thus, only methodological key data are summarized in this communication.

2.1 | Patients

This study population comprised 21 patients receiving 37 implants from February 2008 until May 2009 in extraction sites followed by immediate provisionalization.

One patient with three implants resigned from the study after final delivery of the prosthesis at 4 months. She moved to a foreign country and was not able to visit the follow-up examinations. Another patient with one implant showed up at 30 months for her 2-year follow-up visit and moved afterward to an unknown location. All other 19 patients attended at least the 5-year follow-up visit.

2.2 | Ethical approval

This study was approved by the Ethics committee of the county Rheinland-Pfalz, Germany (file no. 837.063.08 (6060)), and conducted according to the recommendations of good clinical practice. The study was supported by a grant from Astra Tech AB, Sweden, to the Department of Oral and Maxillofacial Surgery, University Medicine of Mainz, Germany. Written Informed Consent was obtained from all patients prior to any examination/treatment carried out for study purposes.

2.3 | Surgical technique

In brief, OsseoSpeed™ implants (Dentsply Sirona Implants, Mannheim, Germany) used in this study were screw-shaped and self-tapping implants with a double-hex conical implant–abutment interface and a MicroThread™ design characterizing the marginal part of the implant. Implants with a cylindrical or a conical/cylindrical design were used. The implant dimensions ranged between 11 and 17 mm in length and 3.5 to 5 mm in diameter. All implants were placed in contact to the palatal lamella of the socket and aligned to the peri-implant hard and soft tissue levels. Placement depth was determined by the facial soft tissue (3 mm apical to target soft tissue level) and palatal bone height (0.5 mm below palatal bone crest).

In all patients, simultaneous bone grafting of the facial gap between implant surface and facial tissues was performed by condensing bone chips to the bottom of the defect with a plugger. Autogenous bone grafts were either harvested at the mandibular ramus and particulated in a bone mill (R. Quetin Bone-Mill, Leimen, Germany) or were retrieved by collecting bone particles by a disposable filter (BoneTrap, Dentsply Sirona Implants). Additional soft tissue grafts were not used.

2.4 | Immediate and final restoration

For single tooth cases, acrylic denture teeth were adjusted and cemented on top of titanium abutments (n = 12) (TiDesign™, Dentsply Sirona Implants). In multiple teeth replacements, screw-retained restorations were fabricated by a laboratory technician (n = 7, 21 implants). All temporary restorations were inserted at the day of implant

placement. The immediate restorations were splinted to neighboring teeth or to each other. The patients were advised to keep a soft and liquid diet for 8 weeks.

After a minimum of 3 months, the final zirconia crowns or bridges were cemented on top of zirconia abutments (Atlantis™ zirconia abutment or ZirDesign™, Dentsply Sirona Implants).

2.5 | Follow-up and definition of outcome variables

The patients were examined at the time of implant placement, at prosthetic delivery, at 1-, 2-, and 5-year follow-up visit following implant insertion (Figure 1).

2.6 | Evaluation of primary outcome variables

The status of the interproximal marginal bone level was assessed using digital periapical radiographs. Attachment levels crestal to reference level (implant shoulder level) were designated as positive values and vice versa.

The thickness of the facial bone wall was determined by CB-CT data, specifically by the reconstruction according to the long axis of the teeth/implants at pre-treatment examination, and at 1-, 2-, or 5-year follow-up (Figure 1a,b). The thickness of the facial bone wall was measured 1, 3, and 6 mm apical to this reference level at the facial aspect of the implant (Buser et al., 2013; Januario et al., 2011).

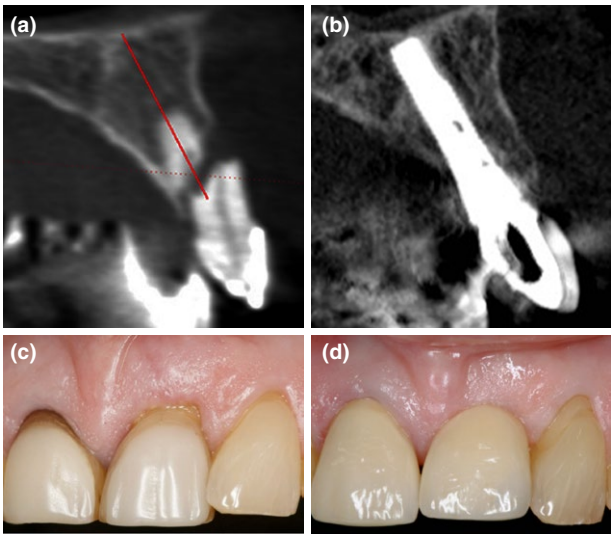

FIGURE 1 Immediate implant insertion, immediate reconstruction, and immediate provisionalization in case of recession-type defect and total loss of the facial bone wall. (a) The CB-CT at pre-operative examination is showing the severe facial bone defect following a horizontal root fracture. (b) The CB-CT at 5-year follow-up visit is presenting the facial bone reconstruction to the level of the implant shoulder. (c) Initial situation of a left central incisor showing soft tissue swelling and slight recession following a horizontal root fracture (PES 11). (d) The clinical situation at 5-year follow-up following immediate implant insertion, provisionalization, and flapless reconstruction shows matured and increased facial peri-implant tissues (PES 12)

2.7 | Evaluation of secondary outcome variables

Implant success was rated according to the criteria established by Buser (Buser, Weber & Lang, 1990).

Additionally, these implant success criteria established by Buser were combined with the criterion of bone loss less than 1 mm at the facial or the interproximal aspect (mean between mesial and distal measurement).

The Pink Esthetic Score (PES) according to Fürhauser (Fürhauser et al., 2005) was also measured prior to surgery and at each follow-up visit (Figure 1c,d).

2.8 | Statistical analysis

To maintain conclusiveness, the statistic analysis essentially carried on with the methodology applied at the 2-year follow-up. Specifically, the analysis exploring the linkage between marginal bone and PES utilized the Spearman's rank-based correlations. Subpopulations within the study group (improved vs. decreased PES, single vs. multiple implant restoration, smokers vs. nonsmokers) were compared using the nonparametric Mann–Whitney *U* Test. Survival probabilities were estimated by the Kaplan–Meier method on a per-implant basis. The endpoints of interest were implant failure according to the criteria established by Buser et al. (1990). All statistic evaluations were performed on a "per-patient" basis. In case of more than one implant/patient, the implant site with the worst result was selected for each parameter.

The analysis exploring the linkage between initial dimension of the facial bone defect and the variable "soft tissue level" or the thickness of the facial bone at final examination utilized the Spearman's rank-based correlations on a per-implant basis.

The reported *p*-values are two-sided. For graphic description, box plots are given. All calculations were carried out using SPSS 22 (SPSS Inc., Chicago, USA).

3 | RESULTS

3.1 | Interproximal marginal bone level

Marginal bone levels in relation to reference level are presented in Table 1 and in Figure 2. The mean interproximal bone level changed from 0.74 ± 0.85 mm at insertion (n = 32, range from −0.57 to 2.67 mm) to 0.04 ± 0.65 mm at 5-year follow-up (n = 33, range from −1.37 to 1.19 mm).

3.2 | Facial marginal bone thickness

CB-CTs were recorded pre-operatively (n = 17), at 1-year (n = 17), at 2-year (n = 16), and at 5-year postoperatively (n = 19). The thickness of the facial bony lamellae was measured at 1, 3, and 6 mm apical

TABLE 1 Mean interproximal marginal bone level (mm) in relation to the reference level during the observation period

	Implant insertion	Prosthesis delivery	1-year	2-year	5-year
	n = 32	*n* = 26	*n* = 33	*n* = 32	*n* = 33
Mesial					
Mean ± *SD*	0.81 ± 0.86	0.24 ± 0.62	0.17 ± 0.62	0.01 ± 0.58	0.08 ± 0.64
Median	0.59	0.29	0.00	0.00	0.00
Distal					
Mean ± *SD*	0.68 ± 0.97	0.09 ± 0.69	0.13 ± 0.63	−0.12 ± 0.61	0.01 ± 0.72
Median	0.55	0.13	0.00	0.00	0.00
(Mesial + distal)/2					
Mean ± *SD*	0.74 ± 0.85	0.17 ± 0.57	0.15 ± 0.59	−0.05 ± 0.54	0.04 ± 0.65
Median	0.57	0.20	0.14	0.00	0.00

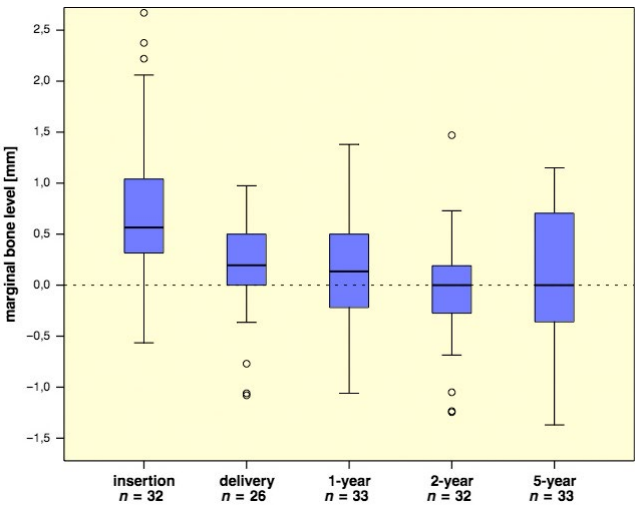

FIGURE 2 Marginal bone level changes over the course of the 5-year follow-up in relation to the reference level (implant shoulder)

to reference level and showed increased thickness of the facial bone (Table 2a). The number of cases presenting no detectable facial bone at the different levels is shown in Table 2b.

3.3 | Implant success according to Buser criteria

Within the follow-up period of 68 ± 9 months (range 57 to 82 months, median: 68 months), no implant had to be removed. Thirty-two implants (97%) fulfilled the success criteria according to Buser (Buser et al., 1990). On retrospective analysis, a facial bone loss of 2.2 mm occurred due to (initially unrecognised) cement over-extrusion to the sulcus at 2.5 years following implant insertion by recementation of the final crown. Three years later, this patient presented with purulent sulcular outflow. After cement removal was performed, the defect recovered without further surgical intervention. Until now, the implant does not show unfavorable esthetic outcome or renewed suppuration. Nevertheless, this case (patient no. 6) was considered as failure.

3.4 | Implant success including bone loss less than 1 mm

At the 5-year follow-up visit, we found a substantial marginal bone loss in the facial midline of a central incisor implant on the CB-CT (patient no. 15). The distance between the remaining bone support and the implant shoulder at this site was 10.6 mm. Another implant presented with no detectable bone at 3- and 6-mm level, but a thin marginal bone portion at the 1-mm level. Surprisingly, there were no clinical symptoms and only minor facial probing depth of 2 mm in both cases. Although those implants formally fulfilled the success criteria according to Buser, they were considered as failures according to the combined success criteria due to the obvious breakdown of bony integrity.

Three implants showed a decrease in the interproximal and another six implants had recessions of the facial marginal bone level to more than 1 mm apical to the reference level within the observation period. According to the second endpoint definition combining the success criteria established by Buser with the criterion of a bone loss smaller or equal than 1 mm, the cumulative success rate according to this second endpoint was 70%.

3.5 | Esthetics

The pre- to 5-year postoperative changes of the PES according to Fürhauser (Fürhauser et al., 2005) are displayed in Table 3 and Figure 3. The mean PES changed from 10.7 ± 2 pre-operatively to 11.7 ± 2 at the 5-year follow-up visit (p = .02). The most critical variable of the PES was the contour of the alveolar process, which decreased from 2 ± 0.2 pre-op to 1.7 ± 0.5 at the 5-year follow-up. An improved or stable score of the PES was noticed in 25 implant sites (76%) (pre-op 10.3 ± 2.2 (range, from 5 to 13), final 12.4 ± 1.4 (range, from 8 to 14)). In eight sites (24%), the esthetic status sustained slight to moderate decrease (pre-op 11.7 ± 1 (range, from 10 to 13), final 9.5 ± 2 (range, from 6 to 12)).

Thus, overall, the "Pink Esthetic Score" was slightly improved with the surgical and prosthetic intervention.

TABLE 2 a and b: Mean facial bone thickness (mm) and number of cases with no detactable facial bone 1, 3, and 6 mm apical to reference level during the 5-year observation period

	pre-op	1-year	pre-op to 1-year *p* =	2-year	1- to 2-year *p* =	5-year	2- to 5-year *p* =
1 mm	0.06 ± 0.20	1.19 ± 0.84	0.000	1.21 ± 0.93	0.191	1.18 ± 0.92	0.879
3 mm	0.46 ± 0.43	1.24 ± 0.88	0.000	1.28 ± 0.95	0.657	1.28 ± 0.95	0.524
6 mm	0.54 ± 0.39	1.03 ± 0.86	0.002	1.16 ± 0.73	0.300	1.11 ± 0.69	0.642
Number of cases with no detactable facial bone at level	**pre-op**	**1-year**		**2-year**		**5-year**	
1 mm	27 (90%)	5 (16.1%)		4 (13.3%)		4 (12.1%)	
3 mm	10 (33.3%)	2 (6.5%)		0 (0%)		3 (9.1%)	
6 mm	5 (16.7%)	4 (12.9%)		1 (3.3%)		2 (6.1%)	

3.6 | Correlation results

Like in the 2-year results, we found no significant correlation between marginal bone level and PES ($r = -.137$; $p = .575$: Spearman's rank correlation coefficient (two-tailed)). However, there was a significant correlation between the PES variable of the alveolar process contour and the thickness of the buccal bone plate (at level 1 mm below implant shoulder) ($r = .459$; $p = .048$), indicating that the thickness of the facial bone lamella emerges as the most critical factor of the long-term esthetic outcome.

In contrast to the 2-year results, there were no significant differences when comparing the esthetic results or the marginal bone level of single vs. multiple implant restoration (PES: $p = .051$; bone level: $p = .442$). For smoker vs. nonsmokers, still, no differences were found (PES: $p = .947$; bone level: $p = .655$).

TABLE 3 Mean score (*SD*) of the variables of the PES according to Fürhauser during the observation period

	Pre-op	1-year	2-year	5-year
Papilla mesial	1.4 ± 0.5	1.4 ± 0.5	1.1 ± 0.6	1.4 ± 0.6
Papilla distal	1.3 ± 0.6	1.4 ± 0.5	1.2 ± 0.6	1.4 ± 0.7
Soft tissue level	1.4 ± 0.7	1.8 ± 0.5	1.9 ± 0.4	1.8 ± 0.4
Soft tissue contour	1.8 ± 0.4	1.8 ± 0.5	1.8 ± 0.4	1.8 ± 0.5
Alveolar process	2 ± 0.2	1.8 ± 0.4	1.6 ± 0.5	1.7 ± 0.5
Soft tissue color	1.4 ± 0.6	1.9 ± 0.3	1.9 ± 0.2	1.8 ± 0.4
Soft tissue texture	1.4 ± 0.6	1.9 ± 0.2	1.9 ± 0.3	1.9 ± 0.4
Sum PES	10.7 ± 2	11.9 ± 1.6	11.3 ± 1.8	11.7 ± 2
Median	11	12	12	12
Range	5–13	6–14	6–14	6–14

The 5-year esthetic result for the thin biotype sites ($n = 9$) was 11.8 ± 1.7, for normal sites 12.5 ± 0.7 ($n = 2$), and for thick sites 11.4 ± 2.8 ($n = 8$). The variable "soft tissue level" was at 5-year follow-up for the thin biotype sites 1.7 ± 0.5, for normal sites 2 ± 0, and for thick sites 1.9 ± 0.4 on a per-patient basis.

Neither the soft tissue level ($p = .394$) nor the amount of final bone regeneration at 1 ($p = .982$), 3 ($p = .864$), or 6 mm ($p = .959$) correlated to the pre-existing facial bone defect.

4 | DISCUSSION

This study evaluates the mid- to long-term results of immediately inserted and provisionalized Astra Tech OsseoSpeed™ implants in the esthetic zone of the maxilla. The recent data allow a comparative analysis of 2-year and later 5-year results, as we used the same outcome parameters in both investigations.

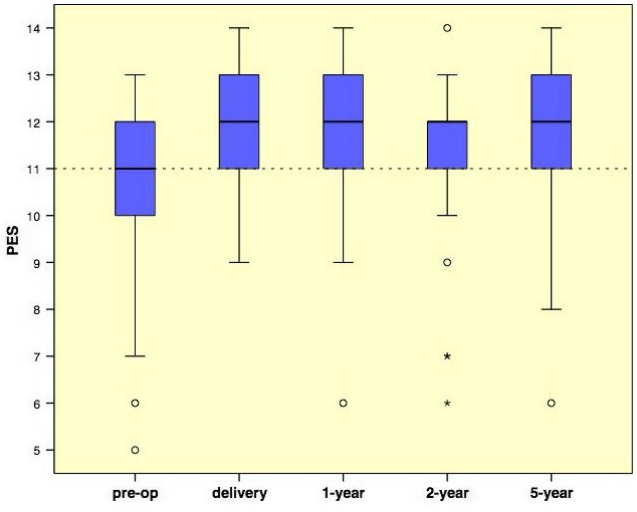

FIGURE 3 Improvement of the PES during the 5-year follow-up examinations

Besides consistent overall implant survival within this prolonged observational period, we found an almost unchanged interproximal bone level (27 months: −0.1 ± 0.55 mm vs. 68 months: 0 ± 0.7 mm). However, we recognized three cases of major bone loss at the facial contour. One, owing to cement overextrusion, meanwhile, recovered spontaneously after cement removal. The etiology of the bone loss in the two further cases remained obscure so far; thus, we have to consider those implants to be "at risk" for further adverse effects on the esthetic outcome.

Arora et al. (2017) found some gains in bone levels of 0.18 and 0.34 mm mesially and distally in relation to baseline at implant insertion. Cosyn et al. (2016) evaluated low-risk cases with single immediate implants in the esthetic zone and reported a mean marginal bone loss of 0.12 mm at 1-year and 0.19 mm at 5-year follow-up with the moment of implant installation as baseline. Another prospective 5-year multicenter study compared the crestal bone level stability following immediate loading of single OsseoSpeed implants placed into healed ridges or extraction sites with intact facial bone plate and found the interproximal bone levels at −0.43 mm below the implant shoulder level (Cooper et al., 2014). In another prospective study, both early and immediate loadings of OsseoSpeed implants were analyzed by Mertens and Steveling after 5 years (Mertens & Steveling, 2011). They demonstrated stable bone conditions with a mean marginal bone level of −0.1 mm below implant shoulder.

Thus, the interproximal bone level seems to be quite robust against different surgical and loading concepts, while the facial bone contour deserves our further attention.

There is only scarce data regarding the dimensional changes of the facial hard tissues following immediate implant placement and facial defect grafting. In a systematic review, Chen and Buser (2014) reported severe resorption with secondary loss of the facial bone wall in 36% (Benic et al., 2012) up to 57% (Miyamoto & Obama, 2011) according to CB-CT data and subsequent recession of the mid-facial mucosa. However, both studies used open surgery after raising a mucoperiosteal flap combined with tissue level implants. Moreover, Benic and Mokti used allografts and collagen membranes for coverage.

In a 2-year prospective study of Arora and Ivanovski (2017), the influence of the pre-operative buccal bone thickness on soft tissue changes around immediately placed and restored implants in the maxillary anterior region was observed. In the presence of an intact buccal bone plate and following flapless implant-socket gap grafting with BioOss, they found slightly reduced soft tissue levels and improved esthetics, which were not influenced by initial buccal bone thickness.

By contrast, we did not raise a flap and the grafting procedure was performed solely with autologous bone. In addition, we used a bone level implant with a platform switch and all implants were immediately provisionalized. These details might be the reason for the more favorable outcome and the rather stable facial bone contour although 15 of 33 sites even had a pre-existing partial or total loss of the facial bony wall.

Buser et al. (2013) observed the long-term stability of the facial bony wall following early single implant placement with contour augmentation in the esthetic zone after a follow-up of 5- to 9-year by CB-CT images. For facial grafting, autogenous bone and BioOss, covered by a Bio Gide membrane, were used. The CB-CT data demonstrated a mean thickness of the facial bone wall of 1.6 mm at 2-mm, of 2.2 mm at 4-mm, and 2.3 mm at 6-mm level. Eight of 41 implants (19.5%) did not show a facial bone wall at 2-mm level, and in two implants (4.9%), no facial bone wall was detectable at 4- and 6-mm levels. When analyzing our data in an analogous manner (Table 2b), our CB-CT data demonstrated a mean thickness of the facial bone wall of 1.2 mm at 1-mm, of 1.3 mm at 3-mm, and 1.1 mm at 6-mm level. We found a lack of facial bone in 12.1% of the implants at the 1-mm, in 9.1% at the 3-mm, and in 6.1% at the 6-mm level. Thus, both concepts imply virtually comparable risks for facial bone resorption in the long run with slight differences for bone thickness in favor of early open implant placement and for bone height in favor of immediate flapless implant placement.

In addition, we found that the esthetic outcome parameter PES remained largely stable comparing the 2-year and the 5-year follow-up data: 11.3 ± 1.8 to 11.7 ± 2 (p = .068). Long-term data regarding peri-implant soft tissue changes for immediate implants are rare and inconsistent.

Cosyn et al. (2016) report esthetic complications in eight of 17 immediate NobelActive implants (5 early and 3 late esthetic complications) in low-risk cases grafted flaplessly with bovine bone particles. They witnessed some decrease in the PES from 12.2 at 1-year to 11.2 at 5-year. On the other hand, Arora et al. (2017) reported a certain improvement in the PES from 10.3 to 11.5 after a 2 to 5-year follow-up using the same treatment strategy as described by Cosyn et al. (2016) but using OsseoSpeed implants. Another 5-year follow-up study of 77 immediate restorations of single immediate implants in the esthetic zone (Fuerhauser et al., 2017) reported that the PES significantly improved between the 6-month and 1-year follow-up and then remained stable up to the fifth year with a final median of PES 13.

In our study, the mean PES improved from 10.7 pre-operatively to 11.9 at 1-year and hereafter remained almost stable up to the 5-year follow-up visit (PES 11.7), which is largely in line with Fuerhauser and coworkers. As already reported within the 2-year results (Noelken et al., 2014), our 5-year esthetic results were not related to the mucosal biotype, which is line with the systematic review of Khzam et al. (2015). They reported that the presence of a thin biotype did not show any significant negative effect on soft tissue changes after immediate implant placement and restoration of single implants in the anterior maxilla.

In the few studies reporting papilla height changes around immediate implants, this variable was by and large stable or even improved (Cooper et al., 2014; Cosyn et al., 2016). Long-term follow-up studies reported tendency to rebound the papilla height over time (Arora et al., 2017). In our study, we also found improved mesial and distal papilla height level between the 2- and 5-year of follow-up, reaching finally the papilla scores slightly higher than the pre-operative state.

We are all well aware of the limitations of our study due to the hitherto small number of cases. However, we suppose that there are the following key factors which may explain the rather stable and constant results:

1. the flapless procedure may preserve the blood supply of the facial lamella
2. the sole use of autologous bone without any bone substitutes and without membranes may prevent resorption due to foreign body reactions
3. the placement of the implants along with the palatal cortical border of the extraction socket increases primary stability and avoids any crossing of the bony envelope.

Taken together, these specific surgical details point at a clinical significance and might explain the stable esthetic outcome as all these factors contribute to a minimum of inflammatory reactions, which otherwise might promote renewed bone resorption and consecutive soft tissue collapse.

On the other hand, we are fully aware that the reported favorable mid- to long-term results might change in future as there are studies (Cosyn et al., 2016) presenting early and late esthetic complications including severe recessions at 5-year examination and therefore recommend not to use this concept for daily practice. Thereby, they impose specific selection criteria, such as thick tissue biotype and an intact facial socket wall.

However, these obstacles did not seem to have a significant impact on our hard and soft tissue results. Further follow-up is needed to explore whether our technique proves to remain robust against the typical esthetic risk factors on the long run.

5 | CONCLUSIONS

Within the limitations of this 5-year follow-up study, single- or multiple teeth rehabilitation patients can be treated with a favorable esthetic outcome using the immediate implant placement and provisionalization approach even when facial bony defects have to be reconstructed at the same time. Although the interproximal bone levels were largely stable at implant shoulder, 27% of the implants revealed a marginal bone level more than 1 mm apical to implant shoulder at the interproximal or facial aspect. However, this reduction did not affect the PES so far.

ACKNOWLEDGEMENTS

The authors Robert Noelken, Maximilian Moergel, and Wilfried Wagner declare the support of the study by a grant from Astra Tech AB, Sweden, to the Department of Oral and Maxillofacial Surgery, University Medicine of Mainz, Germany.

CONFLICT OF INTEREST

The author Martin Kunkel declares no conflict of interest in relation to this manuscript.

ORCID

Robert Noelken http://orcid.org/0000-0003-2258-7909

REFERENCES

Arora, H., & Ivanovski, S. (2017). Correlation between pre-operative buccal bone thickness and soft tissue changes around immediately placed and restored implants in the maxillary anterior region: A 2-year prospective study. *Clinical Oral Implants Research*, *28*(10), 1188–1194. https://doi.org/10.1111/clr.12939

Arora, H., Khzam, N., Roberts, D., Bruce, W. L., & Ivanovski, S. (2017). Immediate implant placement and restoration in the anterior maxilla: Tissue dimensional changes after 2-5 year follow up. *Clinical Implant Dentistry and Related Research*, *19*, 694–702. https://doi.org/10.1111/cid.12487

Benic, G. I., Mokti, M., Chen, C. J., Weber, H. P., Hammerle, C. H., & Gallucci, G. O. (2012). Dimensions of buccal bone and mucosa at immediately placed implants after 7 years: A clinical and cone beam computed tomography study. *Clinical Oral Implants Research*, *23*(5), 560–566. https://doi.org/10.1111/j.1600-0501.2011.02253.x

Botticelli, D., Berglundh, T., & Lindhe, J. (2004). Hard-tissue alterations following immediate implant placement in extraction sites. *Journal of Clinical Periodontology*, *31*(10), 820–828. https://doi.org/10.1111/j.1600-051X.2004.00565.x

Buser, D., Chappuis, V., Bornstein, M. M., Wittneben, J. G., Frei, M., & Belser, U. C. (2013). Long-term stability of contour augmentation with early implant placement following single tooth extraction in the esthetic zone: A prospective, cross-sectional study in 41 patients with a 5- to 9-year follow-up. *Journal of Periodontology*, *84*(11), 1517–1527. https://doi.org/10.1902/jop.2013.120635

Buser, D., Weber, H. P., & Lang, N. P. (1990). Tissue integration of non-submerged implants. 1-year results of a prospective study with 100 ITI hollow-cylinder and hollow-screw implants. *Clinical Oral Implants Research*, *1*(1), 33–40. https://doi.org/10.1034/j.1600-0501.1990.010105.x

Chen, S. T., & Buser, D. (2009). Clinical and esthetic outcomes of implants placed in postextraction sites. *International Journal of Oral and Maxillofacial Implants*, *24*(Suppl.), 186–217.

Chen, S. T., & Buser, D. (2014). Esthetic outcomes following immediate and early implant placement in the anterior maxilla—a systematic review. *International Journal of Oral and Maxillofacial Implants*, *29*(Suppl.), 186–215. https://doi.org/10.11607/jomi.2014suppl.g3.3

Chen, S. T., Darby, I. B., & Reynolds, E. C. (2007). A prospective clinical study of non-submerged immediate implants: Clinical outcomes and esthetic results. *Clinical Oral Implants Research*, *18*(5), 552–562. https://doi.org/10.1111/j.1600-0501.2007.01388.x

Cooper, L. F., Reside, G. J., Raes, F., Garriga, J. S., Tarrida, L. G., Wiltfang, J., … De Bruyn, H. (2014). Immediate provisionalization of dental implants placed in healed alveolar ridges and extraction sockets: A 5-year prospective evaluation. *International Journal of Oral and Maxillofacial Implants*, *29*(3), 709–717. https://doi.org/10.11607/jomi.3617

Cornelini, R., Cangini, F., Covani, U., & Wilson, T. G. Jr. (2005). Immediate restoration of implants placed into fresh extraction sockets for single-tooth replacement: A prospective clinical study. *The International Journal of Periodontics and Restorative Dentistry*, *25*(5), 439–447.

Cosyn, J., De Bruyn, H., & Cleymaet, R. (2013a). Soft tissue preservation and pink aesthetics around single immediate implant restorations: A 1-year prospective study. *Clinical Implant Dentistry and Related Research*, *15*(6), 847–857. https://doi.org/10.1111/j.1708-8208.2012.00448.x

Cosyn, J., Eghbali, A., De Bruyn, H., Collys, K., Cleymaet, R., & De Rouck, T. (2011). Immediate single-tooth implants in the anterior maxilla: 3-year results of a case series on hard and soft tissue response and aesthetics. *Journal of Clinical Periodontology*, *38*(8), 746–753. https://doi.org/10.1111/j.1600-051X.2011.01748.x

Cosyn, J., Eghbali, A., Hanselaer, L., De Rouck, T., Wyn, I., Sabzevar, M. M., … De Bruyn, H. (2013b). Four modalities of single implant treatment in the anterior maxilla: A clinical, radiographic, and aesthetic evaluation.

Clinical Implant Dentistry and Related Research, *15*(4), 517–530. https://doi.org/10.1111/j.1708-8208.2011.00417.x

Cosyn, J., Eghbali, A., Hermans, A., Vervaeke, S., De Bruyn, H., & Cleymaet, R. (2016). A 5-year prospective study on single immediate implants in the aesthetic zone. *Journal of Clinical Periodontology*, *43*(8), 702–709. https://doi.org/10.1111/jcpe.12571

De Bruyn, H., Raes, F., Cooper, L. F., Reside, G., Garriga, J. S., Tarrida, L. G., … Kern, M. (2013). Three-years clinical outcome of immediate provisionalization of single Osseospeed implants in extraction sockets and healed ridges. *Clinical Oral Implants Research*, *24*(2), 217–223. https://doi.org/10.1111/j.1600-0501.2012.02449.x

De Kok, I. J., Chang, S. S., Moriarty, J. D., & Cooper, L. F. (2006). A retrospective analysis of peri-implant tissue responses at immediate load/provisionalized microthreaded implants. *International Journal of Oral and Maxillofacial Implants*, *21*(3), 405–412.

Evans, C. D., & Chen, S. T. (2008). Esthetic outcomes of immediate implant placements. *Clinical Oral Implants Research*, *19*(1), 73–80.

Ferrus, J., Cecchinato, D., Pjetursson, E. B., Lang, N. P., Sanz, M., & Lindhe, J. (2010). Factors influencing ridge alterations following immediate implant placement into extraction sockets. *Clinical Oral Implants Research*, *21*(1), 22–29. https://doi.org/10.1111/j.1600-0501.2009.01825.x

Fugl, A., Zechner, W., Pozzi, A., Heydecke, G., Mirzakhanian, C., Behneke, N., … Colic, S. (2017). An open prospective single cohort multicenter study evaluating the novel, tapered, conical connection implants supporting single crowns in the anterior and premolar maxilla: Interim 1-year results. *Clinical Oral Investigations*, *21*(6), 2133–2142. https://doi.org/10.1007/s00784-016-2003-0

Fürhauser, R., Florescu, D., Benesch, T., Haas, R., Mailath, G., & Watzek, G. (2005). Evaluation of soft tissue around single-tooth implant crowns: The pink esthetic score. *Clinical Oral Implants Research*, *16*(6), 639–644. https://doi.org/10.1111/j.1600-0501.2005.01193.x

Fuerhauser, R., Mailath-Pokorny, G., Haas, R., Busenlechner, D., Watzek, G., & Pommer, B. (2017). Immediate restoration of immediate implants in the esthetic zone of the maxilla via the copy-abutment technique: 5-Year follow-up of pink esthetic scores. *Clinical Implant Dentistry and Related Research*, *19*(1), 28–37. https://doi.org/10.1111/cid.12423

Januario, A. L., Duarte, W. R., Barriviera, M., Mesti, J. C., Araujo, M. G., & Lindhe, J. (2011). Dimension of the facial bone wall in the anterior maxilla: A cone-beam computed tomography study. *Clinical Oral Implants Research*, *22*(10), 1168–1171. https://doi.org/10.1111/j.1600-0501.2010.02086.x

Kan, J. Y., Rungcharassaeng, K., & Lozada, J. (2003). Immediate placement and provisionalization of maxillary anterior single implants: 1-year prospective study. *International Journal of Oral and Maxillofacial Implants*, *18*(1), 31–39.

Khzam, N., Arora, H., Kim, P., Fisher, A., Mattheos, N., & Ivanovski, S. (2015). Systematic review of soft tissue alterations and esthetic outcomes following immediate implant placement and restoration of single implants in the anterior maxilla. *Journal of Periodontology*, *86*(12), 1321–1330. https://doi.org/10.1902/jop.2015.150287

Le, B. T., Borzabadi-Farahani, A., & Pluemsakunthai, W. (2014). Is buccolingual angulation of maxillary anterior implants associated with the crestal labial soft tissue thickness? *International Journal of Oral and Maxillofacial Surgery*, *43*(7), 874–878. https://doi.org/10.1016/j.ijom.2014.02.009

Mertens, C., & Steveling, H. G. (2011). Early and immediate loading of titanium implants with fluoride-modified surfaces: Results of 5-year prospective study. *Clinical Oral Implants Research*, *22*(12), 1354–1360. https://doi.org/10.1111/j.1600-0501.2010.02123.x

Miyamoto, Y., & Obama, T. (2011). Dental cone beam computed tomography analyses of postoperative labial bone thickness in maxillary anterior implants: Comparing immediate and delayed implant placement. *International Journal of Periodontics and Restorative Dentistry*, *31*(3), 215–225.

Noelken, R., Morbach, T., Kunkel, M., & Wagner, W. (2007). Immediate function with NobelPerfect implants in the anterior dental arch. *The International Journal of Periodontics and Restorative Dentistry*, *27*(3), 277–285.

Noelken, R., Neffe, B. A., Kunkel, M., & Wagner, W. (2014). Maintenance of marginal bone support and soft tissue esthetics at immediately provisionalized OsseoSpeed implants placed into extraction sites: 2-year results. *Clinical Oral Implants Research*, *25*(2), 214–220. https://doi.org/10.1111/clr.12069

Noelken, R., Oberhansl, F., Kunkel, M., & Wagner, W. (2016). Immediately provisionalized OsseoSpeed Profile implants inserted into extraction sockets: 3-year results. *Clinical Oral Implants Research*, *27*(6), 744–749. https://doi.org/10.1111/clr.12651

Paolantonio, M., Dolci, M., Scarano, A., d'Archivio, D., di Placido, G., Tumini, V., & Piattelli, A. (2001). Immediate implantation in fresh extraction sockets. A controlled clinical and histological study in man. *Journal of Periodontology*, *72*(11), 1560–1571. https://doi.org/10.1902/jop.2001.72.11.1560

Sanz, M., Cecchinato, D., Ferrus, J., Pjetursson, E. B., Lang, N. P., & Lindhe, J. (2010). A prospective, randomized-controlled clinical trial to evaluate bone preservation using implants with different geometry placed into extraction sockets in the maxilla. *Clinical Oral Implants Research*, *21*(1), 13–21. https://doi.org/10.1111/j.1600-0501.2009.01824.x

Wöhrle, P. S. (1998). Single-tooth replacement in the aesthetic zone with immediate provisionalization: Fourteen consecutive case reports. *Practical Periodontics and Aesthetic Dentistry*, *10*(9), 1107–1114; quiz 1116.

How to cite this article: Noelken R, Moergel M, Kunkel M, Wagner W. Immediate and flapless implant insertion and provisionalization using autogenous bone grafts in the esthetic zone: 5-year results. *Clin Oral Impl Res*. 2018;29:320–327. https://doi.org/10.1111/clr.13119